The protective effects of *Stachytarpheta jamaicensis* (L.) *Vahl* on LPS-induced hepatic and renal injury in ICR mice

Thiagarajan, S. K.[1], Mahadi, I. H.[2], Jamaluddin, N.[2], Yong Y. K.[1], Liew, P. M.[1], Mat Taib, C. N.[1], Hussain, M. K.[2], Perumal, K. V.[1], Bahari, H.[1]*

[1]Department of Human Anatomy, [2]Department of Biomedical Sciences, Faculty of Medicine and Health Sciences, Universiti Putra Malaysia, 43400 Selangor, Malaysia

Abstract

Stachytarpheta jamaicensis (SJ) is one of the plants that being used as alternative in traditional treatments that possess medicinal properties. SJ has been found to exhibit anti-inflammatory activity in acute and chronic models of inflammation, and thus protects the liver. However, its effect on liver and kidney injury induced by lipopolysaccharide remains unclear. To examine the protective effects of SJ on liver and kidney of LPS-induced endotoxemia in ICR mice via determination of lipid peroxidation and histology assessment. A total of 18 male ICR mice (20-30g, 6-8 weeks) were divided into six groups. Control (CTR) and negative control (NEG) groups received normal saline, while treatment groups received dexamethasone (DEX; 5 mg/kg bodyweight (BW)), and ethyl acid extract of SJ (10,100, and 150mg/kg BW) respectively, for seven days consecutively. On day 8, all groups (except control group) were injected with lipopolysaccharides (LPS; 1mg/kg BW) intradermally. After 1 hour of LPS injection, the mouse were euthanized and livers were excised, weighed and kept for assessment of thiobarbituric acid reactive substances-malondialdehyde (TBARs-MDA) assay and histology assessment by haematoxylin-eosin staining. The SJ supplementation slightly decreased the lipid peroxidation in liver as compared to NEG group. In histology observation, the higher dosage of SJ at 150mg/kg BW improved the structure of hepatocytes and less congestion of central vein. In lesion score of the liver, SJ150 has significantly lower of lesion score compared to NEG. Whereas, in kidney tissue, the supplementation of SJ at 100 and 150 mg/kg BW significantly decreases lipid peroxidation level compared to NEG. In kidney lesion score, SJ150 was significantly lower by 55.32% compared to NEG. Overall, supplementation of SJ in LPS-induced endotoxemia in ICR mice may have potential in lowering lipid peroxidation and preventing liver and kidney injury. Further assessment should be done to explore the mechanisms of SJ in preventing the inflammatory mediators induced by LPS that leads to liver and kidney injury.

Keywords: Lipopolysaccharide**;** *Stachytarpheta jamaicensis*; Lipid peroxidation; Liver; Kidney

ARTICLE INFO

Received 31st August 2018
Received in revised form 7th November 2018
Accepted 12th November 2018
**Corresponding author: Dr. Hasnah Bahari*
Tel: +603 8947 2769 e-mail: haba@upm.edu.my
Copyright Malaysian Journal of Microscopy (2018). All rights reserved. ISSN: 1823-7010 eISSN 2600-7444

Introduction

Lipopolysaccharide (LPS) is define as endotoxin, which are the major part of the outer membrane of a Gram-negative bacteria [1]. The LPS acts as a physical barrier which contributes to the structural integrity that protects the bacteria from any form of chemical attack [2]. LPS also have a profound effect as a marker for detection of bacterial pathogen invasion by the immune system [3-6]. When LPS-induced host is infected, monocytes or macrophages will be activated resulting in a series of signaling events that start the production of inflammatory mediators [7]. Lipid peroxidation is caused by the production of oxygen free radicals that leads to the loss of lipids membrane as well as distract the membrane permeability. Lipid peroxidation grow under the stress conditions (hypoxia, sepsis, ischemia or acidosis) as well as in metabolic diseases [8]. Sepsis is a leading problem to multiple organ failure and leads to death [9].

The movement of leukocytes, lymphocytes and platelets decreased the blood flow as well as ischemia injury. This causes the formation of inflammatory cytokines and reactive oxygen species (ROS) that leads to organ failure during the formation of sepsis [10, 11]. There are several comorbidities which are associated with kidney injury, however, chronic liver disease is proposed in this study [12, 13]. These injuries are linked to damage from ROS which produces a variety of lipids and nature free reaction including 4-hydroxyalkenal (4-HDA) and malondialdehyde (MDA) [14]. MDA is a final product of lipid peroxidation, where it serves as a marker to detect the presence of lipid peroxidation [15].

Opiates and non-steroidal anti-inflammatory drugs (NSAIDs) are categorized as the contemporary analgesics and basically goal-directed therapy for anti-inflammatory prevention may not always be suitable for all patients. The usage of high dose steroid such as methylprednisolone and dexamethasone has been a controversy. Dexamethasone for example, is a glucocorticoid class hormone which has anti-inflammatory properties but also a strong immune-suppressant. These treatments have potential side effects and limitation of potency hence, the importance of conventional therapies may slump. Alternatively, natural product which are gaining acceptance to the public plays a vital role in the therapy of human diseases [16].

Locally known as ‘selasih dandi’ or ‘jolok cacing’, *Stachytarpheta jamaicensis* (L.) Vah (SJ) from the *Verbenaceae* family, has asserted medicinal properties used as traditional medicine in parts of South Asia, Indonesia, Philippines and Brunei. They are mostly used to treat rhinitis, malaria, suppress cough and to reduce fever and sores [17]. Preliminary phytochemical investigation carried out on SJ showed abundant metabolites such as saponins, tannins and flavonoids [18, 19]. SJ poses the ability to inhibit extracellular release of free radical and the production of nitric oxide, as well as the ability to demonstrate oxygen scavenging activity which may have pharmaceutical potential to treat immune pathological diseases that related to oxidative stress [20].

It is also claimed that, SJ has the ability to exhibit antacid, analgesic, anti-helmithic, anti-inflammatory, diuretic, hypotensive, laxative, lactogogue, purgative, sedative, stomachictonic, spasmogenic, vasilator, vulnerary and vermifuge protective effect [21, 22]. Others reported pharmacological effects including reduction of motor activity, sedation, ataxia, analgesia, anesthesia, and its active compounds iridoid ipokamiide and verbascoside [23]. Until now, SJ was found to have the ability to reduce histamine release which protects the liver by anti-inflammatory properties [24]. Nonetheless, being claimed for not having

toxicity at high dose and potentially safe and beneficial to human [23], the relationship of LPS induced liver and kidney effect with probable involvement of anti-inflammatory was investigated.

Materials and methods

Preparation of SJ Extract

SJ leaves were collected in Setiawan, Perak, Malaysia and was deposited at the herbarium Institute of Biosciences, Universiti Putra Malaysia with voucher number SK3158/17. The leaves were dried at 50°C for three consecutive days. The leaves were then ground and 500g of the powdered leaves were extracted by using three different solvents from non-polar to polar. First, the powdered leaves were successively extracted with absolute hexane at room temperature until the mixture becomes colorless. The leaves were air dried before soaking in another solvent. The same procedure was applied for the following solvents: ethyl acetate and methanol. The respective extract was then concentrated to dryness by using rotary evaporator under vacuum. Extracts were kept in amber vials and stored at 4°C for further analysis.

Experimental animals

Adult male ICR mice of 6 to 14 weeks, at 25~30 grams, were kept in 70% humidity on a 12/12 hours light/dark cycle in the animal house of the Faculty of Medicine and Health Sciences, Universiti Putra Malaysia (UPM). The animal ethics were approved by the Institutional Animal Care Committee of UPM (ACUC R064/2015). All the mice were fed with standard pellet and tap water *ad libitum.*

LPS-induce liver and kidney injury

A total of 18 male ICR mice (20-30g, 6-8 weeks) were divided into six groups. Control (CTR) and negative control (NEG) groups received normal saline, while treatment groups received DEX (5 mg/kg b.w), and ethyl acid extract of SJ (10,100, and 150mg/kg b.w) respectively, for seven days consecutively. On day 8, all groups (except CTR) were injected with LPS (1mg/kg b.w) intradermally. After 1 hour of LPS injection, the mouse was euthanized. Next, blood, livers and kidneys were excised, weighed and kept for further assessment.

Tissue homogenization

The tissue samples (~0.5g) were homogenized in 5 ml of a cold 0.1M phosphate buffer, pH 7.0. Tissue homogenates were prepared by hand homogenizer and were centrifuged at 10,000g, for 15 min, 4°C and the supernatant was assayed for lipid peroxidation.

Lipid Peroxidation (TBARs Assay)

TBARs assay is a quantitative measurement of lipid peroxidation as MDA which have been used as an index of oxidative stress [15]. The MDA content is an indicator of lipid peroxidation and was assayed by the reaction with TBARs [25]. Generally, 0.2ml of liver homogenate was mixed with 0.5% of thiobarbituric acid (TBA) (2ml, TBA dissolved in 15% trichloroacetic acid (TCA)). The mixture was heated on water bath for 20 minutes. After rapid cooling, the mixture was centrifuged at 10,000g for 10 minutes and the absorbance of the supernatant was measured at 450nm, 500nm, and 600nm. MDA content was calculated as µmol g^{-1} fresh organ weight by using the following formula:

$$6.45\ (A_{532}\text{-}A_{600}) - 0.56A_{450}$$

6.45 = Content of MDA
A_{450} = Error by sample
A_{532} = Maximum absorbance of MDA-TBA complex
A_{600} = Minimum absorbance of MDA-TBA complex

Histology examination

After the organs were obtained and weighed, the organs were immediately immersed into 10% buffered formaldehyde for fixation. After at least 24 hours of fixation in 10% buffered formaldehyde, the organs were embedded in paraffin wax. Once the embedded tissue is ready, the block is sectioned into 5µm thick. The sectioned organs were then placed on slides and stained with haematoxylin and eosin (H&E) staining followed by mounting and examined the slides under a light microscope.

Lesion Score

Lesion score was conducted with slight modifications. The liver scores were made based on these criteria; vacuolization, pyknotic hepatocytes nuclei, activation of kupffer cell and sinusoidal congestion. While, the kidney was scored based on degeneration of tubule, degeneration of Bowman's space, vascular congestion and edema [26]. For each criteria the scores were scored within the range of 0-3 (0-none, 1-mild. 2-moderate, 3-severe).

Statistical Analysis

All data were expressed as mean ± standard deviation and values with $P< 0.05$ were considered as significant. All the data were analyzed by using SPSS 20.0 Windows. One-way analysis of variance (ANOVA) was used to determine the statistical significance by using followed by LSD multiple comparison tests for lipid peroxidation assay. The lesion scoring was analyzed by Kruskal-Wallis non-parametric test followed by the Mann-Whitney test.

Results

The effect of *Starchytarpheta Jamaicensis* (SJ) on the increment of lipid peroxidation on liver and kidney homogenates.

Injuries on liver and kidney can be analyzed by measuring the level of lipid peroxidation induced by the infiltration of LPS in blood. It is well known that the end product of lipid peroxidation, MDA will have a direct damaging effect causing the destruction of membrane lipids which causes a reduction in cell viability and tissue. The MDA level of kidney and liver are as shown in Table 1. In the liver, the negative group (NEG) significantly ($P<0.05$) showed an increase in the lipid peroxidation compared to the control (CTR). The Dexamethasone (DEX), a positive control also showed significant ($P<0.05$) reduction of MDA level compared to NEG, denoting the effectiveness as an anti-inflammatory drug. Whereas, different concentration of SJ supplementation has resulted in a slight reduction of lipid peroxidation in the liver when compared with the negative control. In the kidney, LPS significantly ($P<0.05$) increased the level of MDA compared to CTR. In contrast, DEX has significantly ($P<0.05$) lower of MDA level as compared to NEG. The supplementation of SJ at 100 and 150 mg/kg bodyweight have significantly ($P<0.05$) decreased the MDA level (SJ100 vs NEG; SJ150 vs NEG).

Table 1: Content of MDA in the liver and kidney

Group	CTR	NEG	DEX	SJ10	SJ100	SJ150
	µmol/g tissue fresh weight					
Liver	0.33 ± 0.08[b]	0.55 ± 0.05[a]	0.08 ± 0.04[ab]	0.40 ± 0.04	0.42 ± 0.05	0.42 ± 0.23
Kidney	3.03 ± 0.74[b]	7.86 ± 1.00[a]	3.48 ± 1.06[b]	6.02 ± 2.87[a]	3.62 ± 0.29[b]	2.94 ± 1.15[b]

All values are mean ± SD. [a]$P < 0.05$ was considered significant when compared to control group (CTR). [b]$P < 0.05$ was considered significant when compared to the negative group (NEG).

Histology evaluation on liver and kidney

The histological findings of liver and kidney were shown in Figure 1 and 2 respectively. In liver tissue, there was no abnormal structure observed on the CTR compared to NEG (Fig 1(a)). The histology evaluation on the liver of the NEG showed obvious hepatocyte structure distortion and severe pyknotic hepatocytes nuclei which were absent in the positive control (Figure 1(b)). A smaller amount of congestion in central vein with mild distortion of hepatocytes structures was observed in DEX (Figure 1 (c)). In the group treated with SJ, distortion of hepatocytes structure, moderate activated kupffer cell, and congestion of central vein and sinusoid was observed in SJ10 (Figure 1(d)), while SJ100 exhibit mild hepatocytes disorganization, congestion of central vein, and mild pyknotic hepatocytes nuclei (Figure 1(e)). The SJ150 showed few congestions of the central vein and little pyknotic nuclei which resemble with CTR (Figure 1(f)). Overall, the liver of mice pre-treated with SJ extracts has shown better improvements of the hepatocyte structure, and pathological changes that similar to the control group. In kidney tissue, no abnormal structure was seen in CTR compared to NEG (Figure 2(a)). The negative control (NEG) of the kidney, however, showed extensive bowman's space degeneration, tubular degeneration as well as vascular congestion (Figure 2(b)). The DEX portrayed a reduced degeneration of Bowman's space, tubule and vascular congestion (Figure 2(c)). In the SJ pre-treated group, the morphological structure of kidney tissue shows a decrease of degeneration of Bowman's space, tubule and vascular congestion with increasing dose of SJ (Figure 2 (d), (e), (f)).

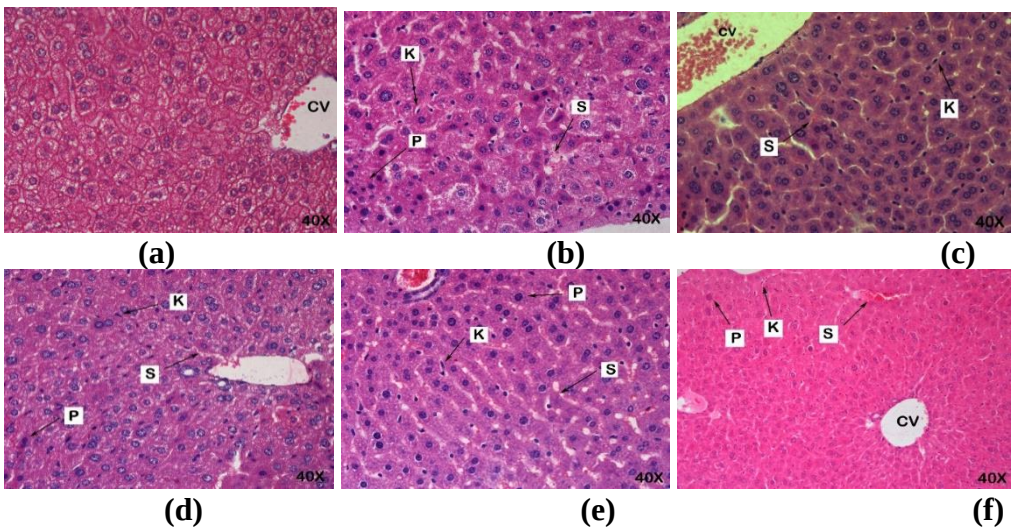

Figure 1: H&E staining of liver tissue. (a) CTR: control group; (b) NEG: negative control; (c) DEX: 5 mg/kg BW of dexamethasone; (d) SJ10: 10 mg/kg BW of *S.Jamaicensis*; (e) SJ100: 100 mg/kg BW of *S.Jamaicensis*; (f) SJ150: 150 mg/kg BW of *S.Jamaicensis*. CV: Central vein; P: Pyknotic nuclei; K: Kupffer cell; S: Sinusoidal congestion. x40 Magnification.

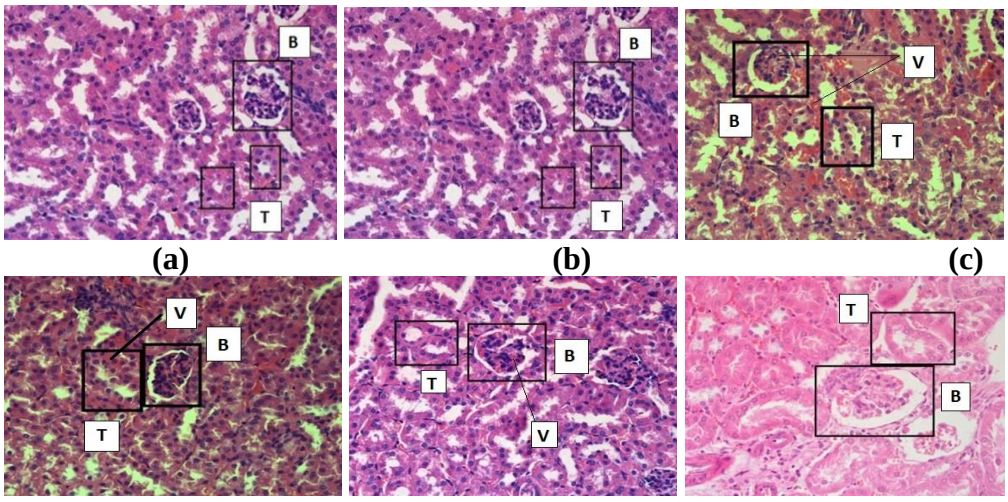

Figure 2: H&E staining of kidney tissue. (a) CTR: control group; (b) NEG: negative control; (c) DEX: 5 mg/kg BW of dexamethasone; (d) SJ10: 10 mg/kg BW of *S.Jamaicensis*; (e) SJ100: 100 mg/kg BW of *S.Jamaicensis*; (f) SJ150: 150 mg/kg BW of *S.Jamaicensis*. B: Bowman's space degeneration, T: Tubule degeneration, V: Vascular congestion. x40 Magnification.

Lesion Score on liver and kidney

The levels of liver injury scores (Table 2) were significant ($P<0.05$) when comparing the NEG group to the CTR group. It is also observed that the higher dose of SJ shows a significant reduced ($P<0.05$) in a number of lesion score when compared to the NEG (SJ150 vs NEG). The levels of kidney injury (Table 2) scores in the NEG group was significantly higher ($P<0.05$) compared to the CTR group. In contrast, the DEX group has shown significantly decreasing ($P<0.05$) level of kidney injury scores as compared to NEG group. The supplementation of SJ at a dosage of 100 and 150 mg/kg BW shown significantly decreasing ($P<0.05$) level of kidney injury scores when compared to the NEG group.

Table 2: Lesion score of the liver and kidney

Group	CTR	NEG	DEX	SJ10	SJ100	SJ150
Liver	0.55 ± 0.05	1.93 ± 0.18[a]	2.05 ± 0.15	1.67 ± 0.33	1.30 ± 0.38	1.27 ± 0.03[b]
Kidney	1.47 ± 0.27	4.70 ± 0.10[a]	2.70 ± 0.23[b]	2.40 ± 0.25	2.13 ± 0.19[b]	2.10 ± 0.25[b]

All values are mean ± SD. [a]$P < 0.05$ was considered significant when compared to control group (CTR). [b]$P < 0.05$ was considered significant when compared to the negative group (NEG).

Discussion

The liver plays an important role against infections particularly bacteria (LPS) in terms of entry regulation and metabolism of LPS upon the exposure [27]. Bacterial infection can be contracted to a human in many ways such as direct infection from an open wound, excessive alcohol consumptions and more. Naturally broken down LPS activates hepatic cells, initiating inflammatory responses [28, 29] releasing chemical mediators such as superoxide, nitric oxide and pro-inflammatory cytokines including tumor necrosis factor alpha, interleukin 1 beta and interleukin 6 [30].

Here, liver injury was induced with LPS which triggers an inflammatory response in the body. Due to an increase of ROS and free radical from activation of Kupffer cells will cause the overproduction of MDA level. This is portrayed in this study where there is a reduction in the TBARs-MDA levels with a slight reduction in lipid peroxidation. In this study, it can be seen that the TBARs-MDA levels were lowered suggesting a reduction in lipid peroxidation. The injected LPS caused an increase in the activity of oxidative stress also altering both histology of liver and kidney. Some of the alterations observed were congestion of central vein, distortion of hepatocytes structure, vacuolization, pyknotic hepatocytes nuclei, dilation and congestion of sinusoidal and the activation of Kupffer cell.

The pre-treatment with SJ marked ameliorated these histopathological changes induced by LPS in SJ150 group (150mg/kg b.w). Liver animals in SJ150 show reduction in all category from the lesion scores which indicates the reduction of LPS effect towards the liver injury. The reduction of MDA levels in this group could be the reason for the protection by SJ towards this group. Furthermore, the discrepancy between the TBARs-MDA result and lesion score between the positive control group and the treatment group could be from the anatomical difference of lobe taken. As mentioned, for histology the largest lobe was taken whereas, for lipid peroxidation other lobe was used. How evenly the occurrence of liver injury was unclear. Thus, we suggest using the same lobe for histology and to another test as well.

Increased of ROS has shown in NEG group with increasing of lipid peroxidation level. The result has shown that, an increase of lipid peroxidation followed by an increase of lesion scoring in the kidney due to LPS-induced acute renal injury. Our finding showed that the destruction of renal structures including glomerulus's space degeneration, tubular degeneration, and vascular congestion. In this study, ethyl acetate SJ treatment show decrease in lipid peroxidation level which is the main indicator for the oxidative stress level occurred due to the inflammation, decrease in the renal scoring level and reduced the morphology structure destruction.

SJ was found to exhibit anti-inflammatory activities in both acute and chronic models of inflammation [22]. While S. cayenensis has found contain triterpenoids and ethyl acetate of SJ extract contained triterpenoids and catechins [31, 32]. The catechins present may show the anti-oxidants effects in this extract [20]. Based on the study, flavonoids such as catechins inhibit ROS production by acting as superoxide scavengers during respiratory burst of rat peritoneal macrophages, while terpenoids act as an immunosuppressant by independent of direct free-radical scavenging mechanism [33, 34].

Conclusion

The ethyl acetate extracts of SJ has beneficial effects in the reduction of oxidative stress as the net ROS production in the kidney. Moreover, helps in the reduction of degeneration in Bowman's space, tubular epithelial cells, and vascular congestion as well as lowering the lesion in the LPS-induced kidney injury in ICR mice. SJ also showed a positive outcome on the LPS-induced liver and kidney injury in ICR mice from lesion scores which indicated the reduction of LPS effect towards the injured liver. The reduction in MDA levels also suggests SJ has the properties to protect the liver and kidney organs.

Acknowledgements

The work was supported by a project grant from Universiti Putra Malaysia (GP-IPM/2014/9433400 and GP-IPS/2016/9472200). Siroshini K Thiagarajan was supported by a Graduate Research Fellowship, UPM and Ministry of Higher Education Malaysia (MoHE).

List of abbreviations

Stachytarpheta jamaicensis : SJ ; Control: CTR; Negative control : NEG; Dexamethasone : DEX; SJ10: 10 mg/kg BW of *S.Jamaicensis* ; SJ100: 100 mg/kg BW of *S.Jamaicensis* ; SJ150: 150 mg/kg BW of *S.Jamaicensis* ; Bodyweight : BW ; Lipopolysaccharides :LPS ; Thiobarbituric acid reactive substances-malondialdehyde : TBARs-MDA; 4-hydroxyalkyl : 4-HDA ; Non-steroidal anti-inflammatory drugs : NSAIDs ; Trichloroacetic acid : TCA ; Malondialdehyde : MDA ; Haematoxylin and eosin : H&E; Analysis of variance : ANOVA; Central vein : CV; Pyknotic nuclei : P; Kupffer cell : K; Sinusoidal congestion :S; Bowman's space degeneration :B; Tubule degeneration : T; Vascular congestion.

Author contributions

All authors contributed toward data analysis, drafting and critically revising the paper and agree to be accountable for all aspects of the work.

Disclosure of conflict of interest

The authors have no disclosures to declare.

References

[1] Xiang, Q., Liu, Z., Wang, Y., Xiao, H., Wu, W., Xiao, C., & Liu, X. (2013). Carnosic acid attenuates lipopolysaccharide-induced liver injury in rats via fortifying cellular antioxidant defense system. *Food and Chemical Toxicology*, *53*, 1–9.

[2] Raetz, C. R. (1993). Bacterial endotoxins: extraordinary lipids that activate eucaryotic signal transduction. *Journal of Bacteriology*, *175*(18), 5745–53.

[3] Bosshart, H., & Heinzelmann, M. (2007). Targeting bacterial endotoxin: Two sides of a coin. In *Annals of the New York Academy of Sciences* (Vol. 1096, pp. 1–17).

[4] Silhavy, T. J., Kahne, D., & Walker, S. (2010). The bacterial cell envelope. *Cold Spring Harbor Perspectives in Biology*. Cold Spring Harbor Laboratory Press, *Biol. 2* (2010), 414.

[5] Mayeux, P. R. (1997). Pathobiology of lipopolysaccharide. *Journal of Toxicology and Environmental Health*, *51*(5), 415–435. https://doi.org/10.1080/00984109708984034

[6] Karima, R., Matsumoto, S., Higashi, H., & Matsushima, K. (1999). The molecular pathogenesis of endotoxic shock and organ failure. *Molecular Medicine Today*. Karger Publishers, 5, 123–32.
[7] Fujii, E., Yoshioka, T., Ishida, H., Irie, K., & Muraki, T. (2000). Evaluation of iNOS-dependent and independent mechanisms of the microvascular permeability change induced by lipopolysaccharide. *British Journal of Pharmacology*, *130*(1), 90–94.
[8] Patočková, J., Kršiak, M., Marhol, P., & Tůmová, E. (2003). Cerebrolysin inhibits lipid peroxidation induced by insulin hypoglycemia in the brain and heart of mice. *Physiological Research*, *52*(4), 455–460.
[9] Hsu, S. P., Chen, C. C., & Chien, C. T. (2016). Pretreatment of Sialic Acid Efficiently Prevents Lipopolysaccharide-Induced Acute Renal Failure and Suppresses TLR4/gp91-Mediated Apoptotic Signaling. *Kidney and Blood Pressure Research*, *41*(3), 267–277.
[10] Ho, C. H., Hsu, S. P., Yang, C. C., Lee, Y. H., & Chien, C. T. (2009). Sialic acid reduces acute endotoxemia-induced liver dysfunction in the rat. *Shock*, *32*(2), 228–235.
[11] Bhattacharyya, J. ., Biswas, S. ., & Datta, A. G. (2004). Mode of action of endotoxin: Role of free radicals and antioxidants. *Current Medicinal Chemistry*, *11*(3), 359–368.
[12] Cruz, D. N., & Ronco, C. (2007). Acute kidney injury in the intensive care unit: Current trends in incidence and outcome. *Critical Care*, *11*(4), 149.
[13] Ali, T., Khan, I., Simpson, W., Prescott, G., Townend, J., Smith, W., & MacLeod, A. (2007). Incidence and Outcomes in Acute Kidney Injury: A Comprehensive Population-Based Study. *Journal of the American Society of Nephrology*, *18*(4), 1292–1298.
[14] Gutteridge, J. M. C., & Halliwell, B. (1990). The measurement and mechanism of lipid peroxidation in biological systems. *Trends in Biochemical Sciences*, *15*(4), 129–135.
[15] Moon, J. E., Shin, J.-H., Kwon, O., & Kim, J. Y. (2015). A Standardized Extract of Rhus verniciflua Stokes Protects Wistar Rats Against Lipopolysaccharide-Induced Acute Inflammation. *Journal of Medicinal Food*, *18*(11), 1223–1230.
[16] Vongtau, H. O., Abbah, J., Mosugu, O., Chindo, B. A., Ngazal, I. E., Salawu, A. O., Gamaniel, K. S. (2004). Antinociceptive profile of the methanolic extract of Neorautanenia mitis root in rats and mice. *Journal of Ethnopharmacology*, *92*(2–3), 317–324.
[17] Henderson, A., Wagner, W. L., Herbst, D. R., & Sohmer, S. H. (1992). Manual of the Flowering Plants of Hawai'i. *Brittonia*, *44*(1), 73.
[18] Ataman, J. E., Idu, M., Odia, E. A., Omogbai, E. K. I., Amaechina, F., Akhigbe, A. O., & Ebite, L. E. (2006). Histopathologic effects of Stachytarpheta jamaicensis (L.) Vahl. on Wistar rats. *Pakistan Journal of Biological Sciences*, *9*(3), 477–482.
[19] Soares, A., Ticli, F., Marcussi, S., Lourenco, M., Januario, A., Sampaio, S., Pereira, P. (2005). Medicinal Plants with Inhibitory Properties Against Snake Venoms. *Current Medicinal Chemistry*, *12*(22), 2625–2641.
[20] Álvarez, E., Leiro, J. M., Rodríguez, M., & Orallo, F. (2004). Inhibitory effects of leaf extracts ofStachytarpheta jamaicensis(Verbenaceae) on the respiratory burst of rat macrophages. *Phytotherapy Research*, *18*(6), 457–462.
[21] Melita Rodríguez, S., & Castro, O. (1996). [Pharmacological and chemical evaluation of stachytarpheta jamaicensis (Verbenaceae)]. *Revista de Biologia Tropical*, *44*(2A), 353–9.
[22] Sulaiman, M. R., Zakaria, Z. A., Chiong, H. S., Lai, S. K., Israf, D. A., & Azam Shah, T. M. (2009). Antinociceptive and Anti-Inflammatory Effects of <i>Stachytarpheta jamaicensis </i>(L.) Vahl (Verbenaceae)in Experimental Animal Models. *Medical Principles and Practice*, *18*(4), 272–279.
[23] Idu, M., Omogbai, E. K. I., Aghimien, G. E., Amaechina, F., Timothy, O., & Omonigho, S. E. (2007). Preliminary Phytochemistry, Antimicrobial Properties and Acute Toxicity

of Stachytarpheta jamaicensis (L.) Vahl.Leaves. *Trends in Medical Research*, *2*(4), 193–198.

[24] Xiong, Q., Hase, K., Tezuka, Y., Tani, T., Namba, T., & Kadota, S. (1998). Hepatoprotective activity of phenylethanoids from Cistanche deserticola. *Planta Med*, *64*(2), 120–125.

[25] Wang, L., Llorente, C., Hartmann, P., Yang, A.M., Chen, P., Schnabl, B. (2015). Methods to determine intestinal permeability and bacterial translocation during liver disease. *Journal of Immunological Methods*, 421, 44–53.

[26] Ibrahim, M. Y., Bustamam, A., Abdul, H., Azmi, T., Ibrahim, T., Abdelwahab, S. I., Syam, M. M. (2010). Evaluation of Acute Toxicity and the Effect of Single Injected Doses of Zerumbone on the Kidney and Liver Functions in Sprague Dawley rats. *African Journal of Biotechnology*, *9*(28), 4442–4450.

[27] Ajuwon, O. R. azaq, Oguntibeju, O. O. moniyi, & Marnewick, J. L. ucasta. (2014). Amelioration of lipopolysaccharide-induced liver injury by aqueous rooibos (Aspalathus linearis) extract via inhibition of pro-inflammatory cytokines and oxidative stress. *BMC Complementary and Alternative Medicine*, *14*(1), 392.

[28] Enomoto, N., Ikejima, K., Kitamura, T., Oide, H., Takei, Y., Sato, N., & Thurman, R. G. (2000). Alcohol enhances lipopolysaccharide-induced increases in nitric oxide production by Kupffer cells via mechanisms dependent on endotoxin. *Alcohol Clin Exp Res*, *24*(4 Suppl), 55S–58S.

[29] McClain, C. J., Song, Z., Barve, S. S., Hill, D. B., & Deaciuc, I. (2004). Recent Advances in Alcoholic Liver Disease IV. Dysregulated cytokine metabolism in alcoholic liver disease. *Am J Physiol Gastrointest Liver Physiol*, *287*(3), G497–G502.

[30] Lee, K.-H., Yeh, C.-C., Lee, J.-W., Chen, J.-Y., Chang, C.-L., Ho, T.-Y., … Chi, C.-H. (2010). The anti-inflammatory activity of Taraxacum Mongolicum in bovine subclinical mastitis and in lipopolysaccharide-stimulated milk cells. *Journal Of Livestock Science*, *2*, 20–32.

[31] Hammer, M. L. A., & Johns, E. A. (1993). Tapping an Amazônian plethora: four medicinal plants of Marajó island, Pará (Brazil). *Journal of Ethnopharmacology*, *40*(1), 53–75.

[32] Schapoval, E. E. S., Winter De Vargas, M. R., Chaves, C. G., Bridi, R., Zuanazzi, J. A., & Henriques, A. T. (1998). Antiinflammatory and antinociceptive activities of extracts and isolated compounds from Stachytarpheta cayennensis. *Journal of Ethnopharmacology*, *60*(1), 53–59.

[33] Liebgott, T., Miollan, M., Berchadsky, Y., Drieu, K., Culcasi, M., & Pietri, S. (2000). Complementary cardioprotective effects of flavonoid metabolites and terpenoid constituents of Ginkgo biloba extract (EGb 761) during ischemia and reperfusion. *Basic Research in Cardiology*, *95*(5), 368–377.

[34] Sasaki, H., Nishimura, H., Morota, T., Chin, M., Mitsuhashi, H., Komatsu, Y., Xiong, Y. L. (1989). Immunosuppressive principles of Rehmannia glutinosa var. hueichingensis. *Planta Medica*, *55*(5), 458–462.